

# IVORY Graft

## Case Report

**Patient:** Male patient 69 year old

**Medical condition:** Implant with an apical cyst (in tooth area 11)

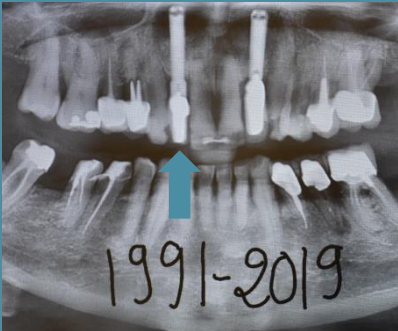**Graft:** Ivory's Dentin Bone Graft (2 grams)

**Application:** Augmentation at apex area 11 (and implant replacement)

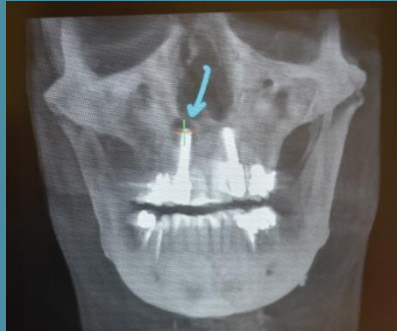
**By:** Dr. Gerard Scortecci, D.D.S, Ph.D., Nice, France

### Before Implant Extraction and Bone Grafting

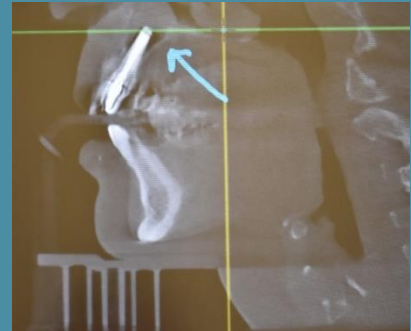
Note the apical cyst in the CBCT scans below



Panoramic scan



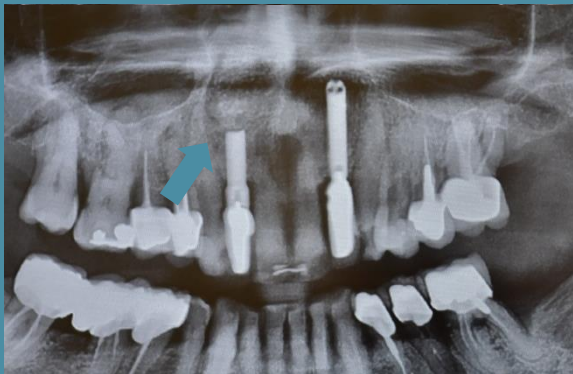CBCT scan (Axial)



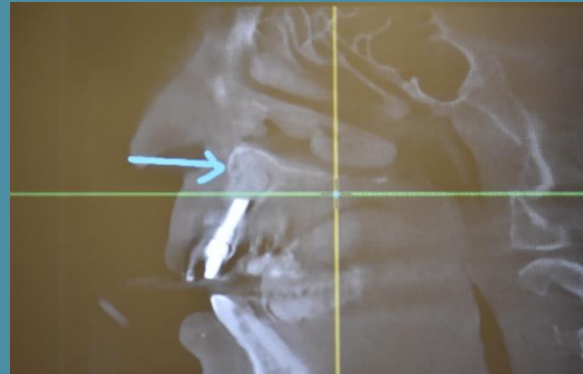
CBCT scan (Sagittal)

### 3 Years After Bone Grafting

Note the reconstructed new apical bone



Panoramic scan



CBCT scan (Sagittal)

**"Robust apical bone reconstruction with Ivory Dentin Graft" Dr. Gerard Scortecci**