

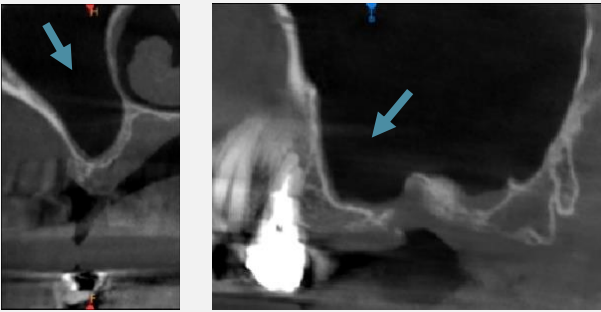
IVORY Graft

Case Report

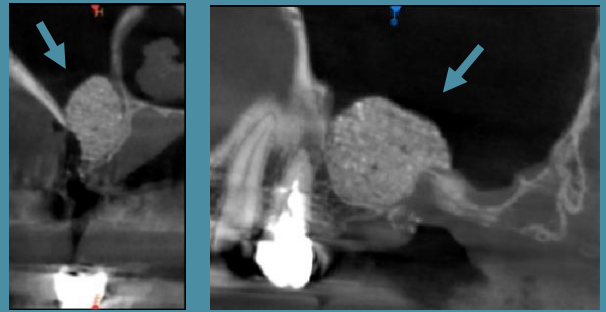
Graft: Ivory's Dentin Bone Graft

Application: Sinus lift, 70 year old woman, no medical problem

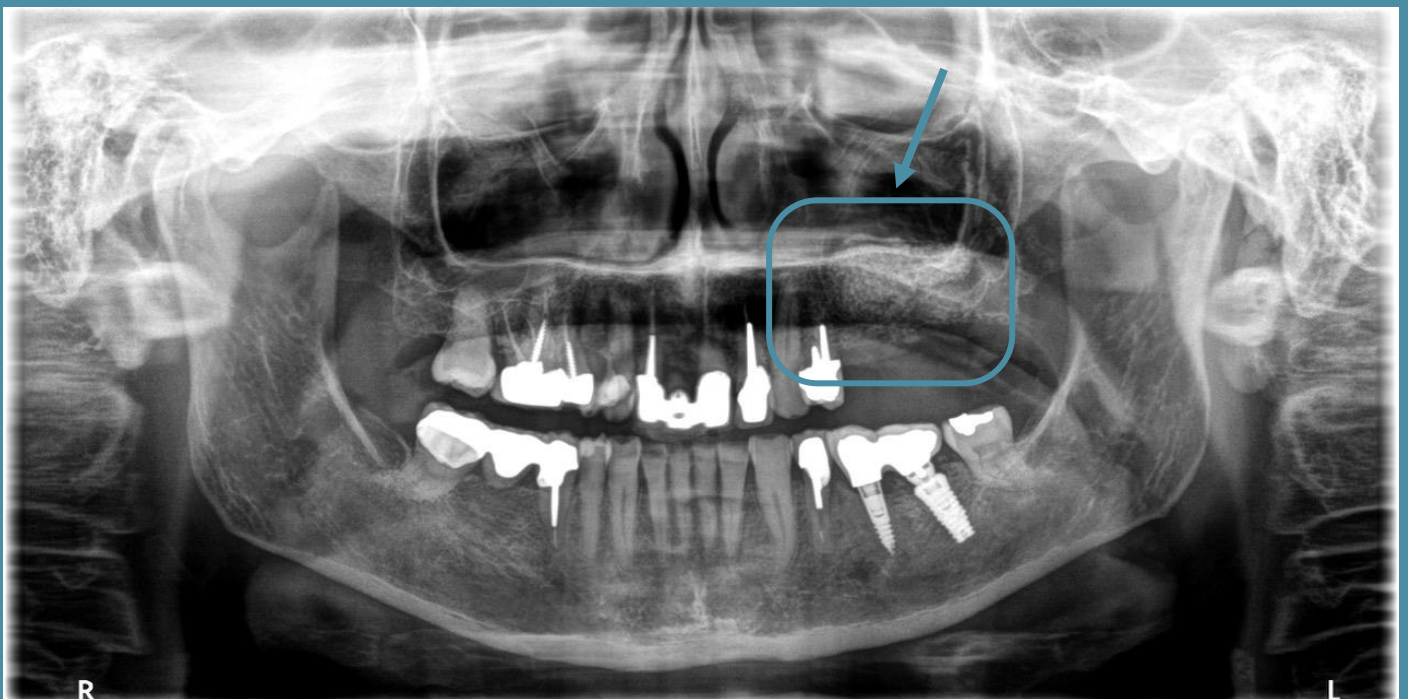
By: Dr. Renaud Petitbois, DMD, France



CBCT scan
Before bone grafting



CBCT scan
Sinus lift completed



CBCT scan
3 month after bone grafting