

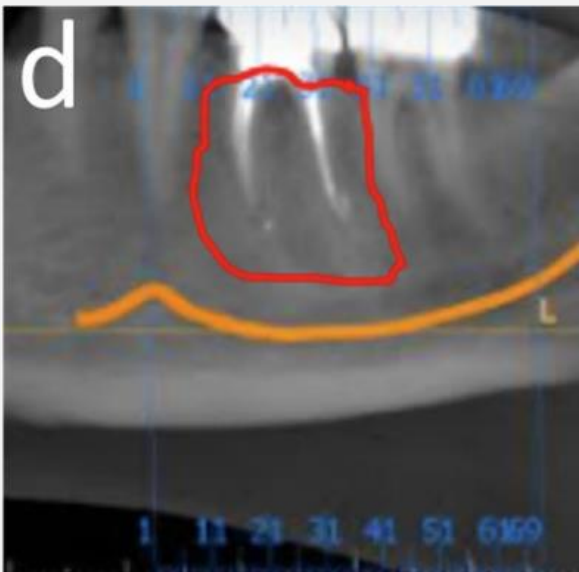
IVORY Graft

Case Report

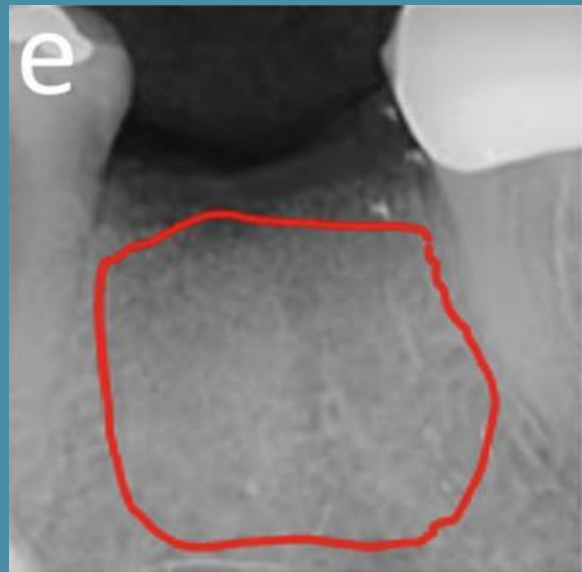
Graft: Ivory's Dentin Bone Graft

Application: Alveolar ridge preservation

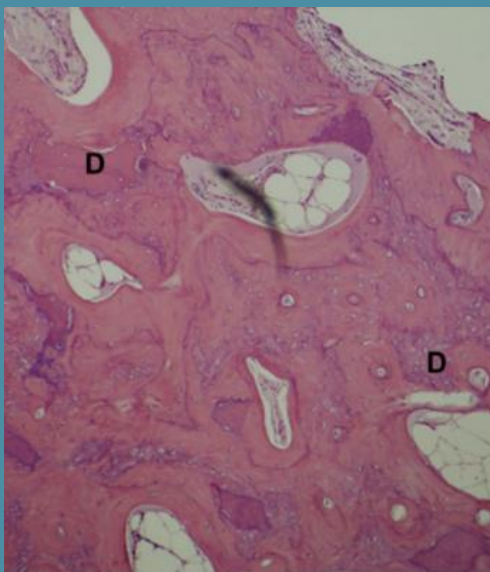
By: Doctors at the Clinic for Oral and Maxillofacial Surgery, Shamir Medical Center



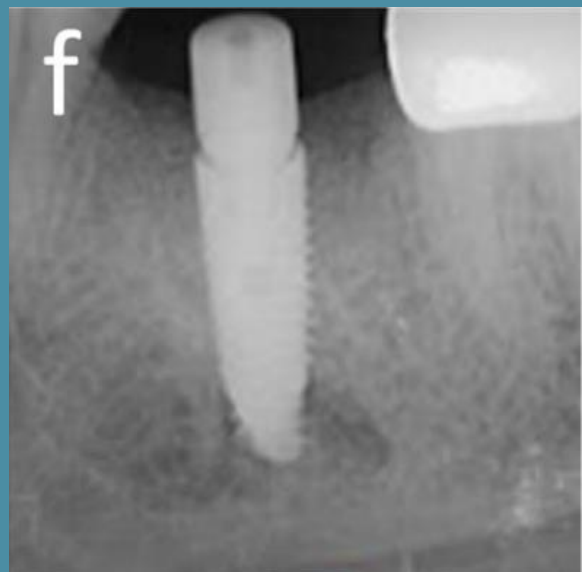
CBCT scan
Before extraction and bone grafting



CBCT scan
4 months after bone grafting



Histology
4 months after bone grafting



CBCT scan
4 months post-grafting - implant placement