

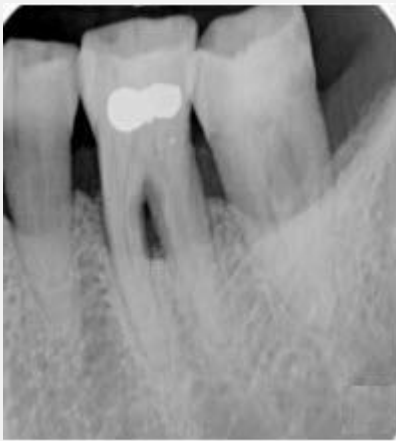# IVORY Graft

## Case Report

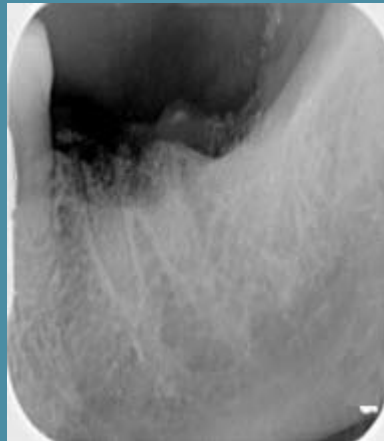**Graft:** Ivory's Dentin Bone Graft

**Application:** Socket preservation

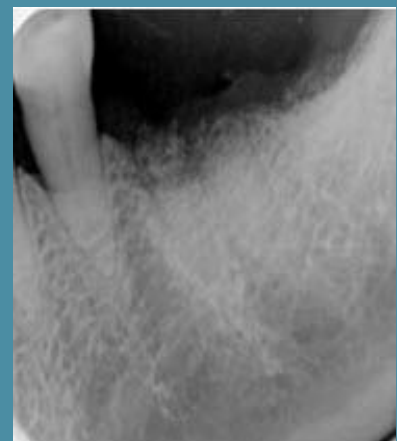**By:** Doctors at the Clinic for Oral and Maxillofacial Surgery, Shamir Medical Center



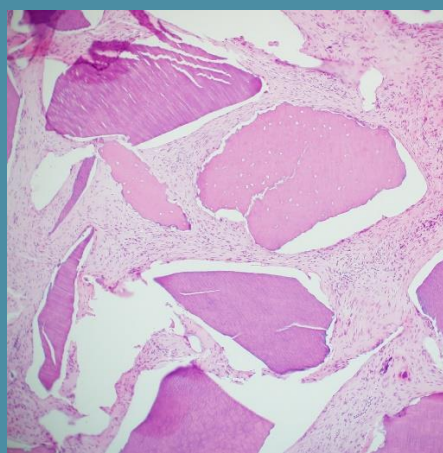
**Periapical x-ray scan**  
Before extraction  
and bone grafting



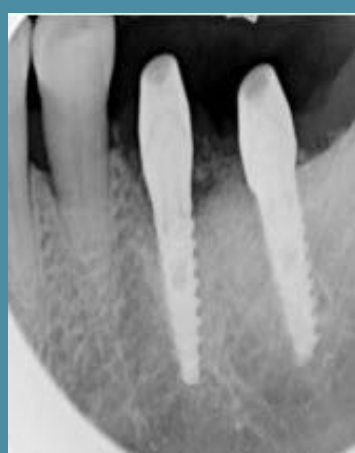**Periapical x-ray scan**  
After extraction  
and bone grafting (a)



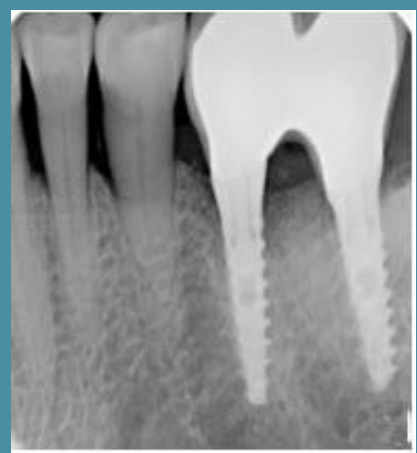**Periapical x-ray scan**  
After extraction  
and bone grafting (b)



**Histology**  
4 months after bone grafting



**Periapical x-ray scan**  
4 months post grafting  
- implant placement



**Periapical x-ray scan**  
4 years after grafting  
- with bridge